

# THE DISTAL LATERAL ARM FLAP FOR RESURFACING OF EXTENSIVE DEFECTS OF THE DIGITS

ANDREA ATZEI, M.D.,<sup>1\*</sup> MARCO PIGNATTI, M.D.,<sup>2</sup> GIORGIO UDALI, M.D.,<sup>1</sup> LANDINO CUGOLA, M.D.,<sup>1</sup>  
and MASSIMO MARANZANO, M.D.<sup>3</sup>

The distal lateral arm flap (DLAF) was used to reconstruct six extensive defects of the digits: 2 degloving injuries of the thumb and 4 major skin losses of the fingers. Two adjacent fingers were involved in 1 patient. Flap size ranged from 3 × 7 cm to 9 × 14 cm. Four flaps were reinnervated using the posterior cutaneous nerve of the forearm. All flaps survived, though 1 showed marginal necrosis. Average follow-up was 53.4 months. Thumb opposition scored 5 according to Kapandji; finger ROM averaged 50.75%; pinch strength 72.5%. Protective sensation with touch localization was restored. Patient satisfaction for resurfaced digits averaged 8.9 on a 10-points visual analogic scale. All donor sites resulted in a painless scar with good patient satisfaction. The DLAF offers a thin, pliable skin ideal for digit reconstruction, with low rate of donor site morbidity and can be considered when toe-to-hand flap transfer is not advisable or refused by the patient. © 2007 Wiley-Liss, Inc. *Microsurgery* 27:8–16, 2007.

**T**raumatic injury to the hand may result in extensive soft tissue loss on the fingers and thumb. Smaller size defects, or when tendon, bone or joint coverage is still preserved, may be treated by simpler reconstructive techniques, such as secondary intention healing, delayed primary closure, or skin graft.<sup>1–3</sup> Larger soft tissue defects, especially when noble or relatively poorly vascularized structures are exposed, are best treated with a pedicled or free flap.<sup>4</sup>

Though local flaps, either homodigital,<sup>5,6</sup> heterodigital,<sup>7</sup> or dorsally based,<sup>8</sup> offer the main advantage of “replacing like with like,” their use is limited by size and location of the defect, due to scant availability of donor tissue in the hand and restricted arc of flap rotation.<sup>4,7–10</sup>

Reconstruction of digital defects by distant pedicled flaps from groin,<sup>11</sup> trunk,<sup>12</sup> or contralateral arm<sup>13</sup> have very limited application, as these flaps provide bulky tissue and require multiple operations with an intervening period of immobilization and dependency.

Use of small free flaps is a valuable surgical option, when local solutions are not applicable. A number of potential donor sites are available for harvesting either cutaneous,<sup>14</sup> fascio-cutaneous,<sup>15</sup> or fascial flaps<sup>16</sup> to be used to resurface digital defects. Many microsurgeons consider the foot region as the preferable donor source for this purpose, given the possibility of harvesting a variety of flaps,

such as the wrap-around toe flap or great-toe hemi-pulp flap for thumb reconstruction, and the instep flap or first-web space flap for finger reconstruction.<sup>17–21</sup>

However, this option may not be applicable due to previous foot injuries or may be refused by some patients for several reasons. Psychosocial and functional concerns, basic preservation of the integrity of the foot as a previously undamaged body part, or religious issues, as in the Buddhist faith,<sup>22</sup> play a negative role in patients' acceptance of a tissue transfer from the foot.

The lateral arm flap (LAF), a recognized versatile transfer with very low donor site morbidity, can be harvested from the same operating field of digital skin loss, using axillary block anesthesia. Use of this flap results in minimal esthetical damage without any major arterial sacrifice.<sup>23,24</sup>

Furthermore, its modification as a “truly distal” LAF allows harvesting of a very thin and pliable skin paddle from the lateral aspect of the proximal forearm,<sup>24–26</sup> which seems to be most suitable for resurfacing of large defects of the digits. This paper reports on the use of the distal lateral arm flap (DLAF) for reconstruction of a series of extensive skin losses on the thumb (average area 115 cm<sup>2</sup>) and fingers (average area 29.12 cm<sup>2</sup>).

## PATIENTS AND METHODS

Between February 2001 and May 2003, the DLAF was used in 5 patients for resurfacing extensive posttraumatic skin loss in 6 digits: the thumb was involved in 2 patients, 1 single finger in 2 patients, and 2 adjacent fingers in another patient. In all cases the nondominant side was affected. All patients were men, with an average age of 44.83 years (range 36–58). Patients' demographics and surgical details are summarized in Table 1.

Each patient was placed in a supine position under axillary block. The arm was positioned over a hand table.

<sup>1</sup>Hand Surgery Unit, Policlinico “G.B. Rossi”, Azienda Ospedaliera-Universitaria, Verona, Italy

<sup>2</sup>Department of Plastic Surgery, Azienda Ospedaliera-Universitaria, Verona, Italy

<sup>3</sup>Maxillofacial Surgery Unit, Regional Hospital “Ca' Foncello”, Treviso, Italy

Work done at the Hand Surgery Unit, Policlinico “G.B. Rossi”, Azienda Ospedaliera-Universitaria, Verona, Italy.

\*Correspondence to: Andrea Atzei, M.D., Hand Surgery Unit, Policlinico “G.B. Rossi”, P.le L.A. Scuro, 10, 37100 Verona, Italy.

E-mail: andrea.atzei@univr.it, andreatzei@libero.it

Received 28 September 2006; Accepted 28 September 2006

Published online 4 January 2007 in Wiley InterScience (www.interscience.wiley.com). DOI 10.1002/micr.20308

Table 1. Patients Demographics and Surgical Details

Case	Age/Sex	Injured digit/Side	Cause	Associated injuries	Skin loss (cm <sup>2</sup> )	Flap dimension (cm × cm)	Flap harvesting time (min.)	Pedicle length (cm)	Donor site closure	Anastomosis	Nerve repair
1	41/M	Thumb/L	Failed replantation	Amputation through IPJ	126	9 × 14	75	8	Direct	T-L Radial A. (distal forearm)	DSB-RN
2	35/M	Thumb/L	Press machine	Amputation through IPJ	104	8 × 13	60	9	Direct	T-L Radial A. (distal forearm)	DSB-RN
3	44/M	Index/L	Rotating machine	None	52	4 × 13	45	8	Direct	T-L Radial A. (anat. snuffbox)	None
4	58/M	Middle/L	Rotating machine (crush - degloving)	Severe crush distal forearm/index amputation/crushed flexor tend.	52	4 × 8	40	9	Direct	T-T collateral A.	Collateral N.
5*	55/M	Middle/R Ring/R	Rotating machine (sharp injury)	Flex. tendon laceration + destroyed DIPJ	15 17.5	6 × 7	55	7	Direct	T-T collateral A.	Collateral N. None
Mean	44.8/M				57.75		55	8.20			

\*Skin defect involved two adjacent fingers and was treated by a single flap in temporary syndactyly.  
IPJ, Inter-Phalangeal Joint; DIP, Distal Inter-Phalangeal Joint; T-L, Termino-lateral anastomosis; T-T, Termino-terminal anastomosis; DSB-RN, Dorsal Sensory Branch of Radial nerve.

The defect was debrided and measured. The most convenient recipient vessels and a sensitive nerve were harvested prior to flap dissection.

The proximal part of the DLAF was outlined over the lateral epicondyle. Care was taken to include the most distal cutaneous perforator arising from the posterior radial collateral artery (PRCA) into the flap (see Fig. 1). Because of its constant finding at about 4–5 cm proximal to the epicondyle,<sup>26,27</sup> no preoperative Doppler investigation was considered necessary. According to the defect's shape, the flap was designed in a heart-shaped fashion when used for thumb reconstruction<sup>28</sup> (see Fig. 2), or classically spindle-shaped for finger reconstruction, with its main axis overlying the line joining the epicondyle to the distal radio-ulnar joint. Flap dissection started from the dorsal incision of the proximal part of the flap, to visualize the distal cutaneous perforator. When the perforator was identified, the distal part of the flap was raised from the epicondylar periosteum and the fascia of the epicondylar muscles. Subsequently, the lateral intramuscular septum between the brachioradialis and the triceps muscle was dissected and the PRC pedicle was harvested from distal to proximal along its intraseptal course, up to the profunda brachii vessels, where it was divided. When used, Esmarch tourniquet was released at this stage of the dissection, to permit division of the vascular pedicle at its most proximal point. The posterior cutaneous nerve of the forearm (PCNF) was raised along with the PRCA pedicle, as the flap paddle coincides with its area of skin innervation.

DLAF harvesting time never exceeded 75 min (average 55 min). The flap size ranged from 3 × 7 cm to 9 × 14 cm. Pedicle length averaged 8.2 cm and sufficed for easy anastomosis in all cases. Arterial anastomosis was performed end-to-end to the collateral digital artery in 2 cases and end-to-side to the radial artery in 3 cases (1 case at the anatomical snuffbox and 2 cases at the distal forearm). Venous anastomosis was performed end to end to the dorsal superficial veins in 2 cases and to the venae comitantes to the radial artery in 3 cases. The PCNF was connected to the DSB-RN in 2 cases and to the collateral digital nerve in 2 cases. In 1 case, a single DLAF was used to cover 2 adjacent fingers and divided late, thus only 1 flap remained innervated via the PCNF. In 1 case, no nerve reconstruction was performed.

Medical records were reviewed for intraoperative and early postoperative complications or reoperations. Patients were assessed at follow-up for donor site morbidity in terms of range of motion (ROM) of the elbow, scar enlargement (mm), scar tenderness, and paresthesia or residual pain over the lateral epicondyle and/or proximal forearm (VAS scale).

To evaluate ROM recovery of the recipient digit, thumb's opposition was measured according to Kapandji

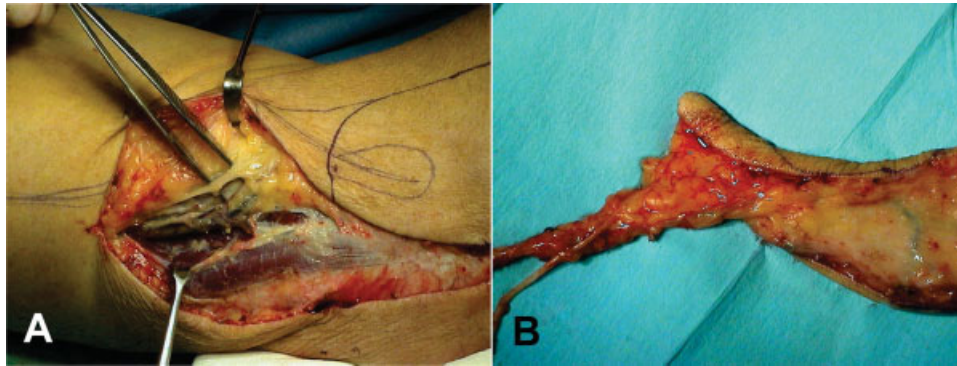


Figure 1. The dorsal margin of the DLAF is incised. The distal cutaneous perforator arising from the posterior collateral radial artery and the PCNF (visualized over the forceps) enters the flap about 4 cm proximal to the epicondyle (A). The neuro-vascular bundle enters the thick upper arm tissue in the proximal part of the flap. The distal part of the flap consists of the more thin and pliable skin and subcutaneous tissue from the proximal forearm (B). [Color figure can be viewed in the online issue, which is available at [www.interscience.wiley.com](http://www.interscience.wiley.com).]

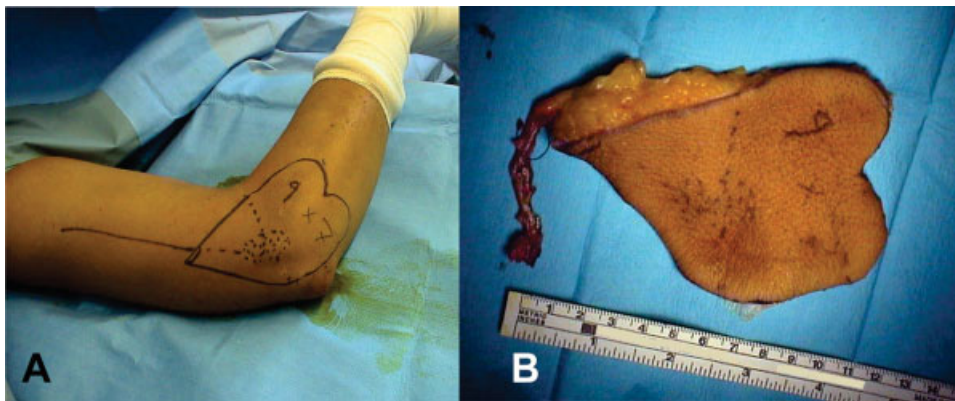


Figure 2. The DLAF for thumb reconstruction. Preoperative design of the heart-shaped flap includes the skin and the fatty subcutaneous tissue overlying the epicondyle. [Color figure can be viewed in the online issue, which is available at [www.interscience.wiley.com](http://www.interscience.wiley.com).]

scale<sup>29</sup> (range 0–10), finger motion was evaluated according to Strickland's TAM criteria<sup>30</sup> and expressed as percentage of normal ROM. Pinch strength was also recorded as percentage of contralateral side. Sensibility was tested for pressure threshold by Semmes–Weinstein monofilaments<sup>31</sup> and discrimination by static and moving 2-point discrimination test.<sup>32,33</sup> Return to previous work and patients' satisfaction for the appearance and function of the donor and recipient site were investigated. The latter was scored on a VAS scale ranging from 0 (completely disappointed) to 10 (completely satisfied) and divided into three classes (Good: 10–8; Fair: 7–5; Poor: <5).<sup>25</sup> The following are cases from our series, numbers 1, 3, and 5.

## CASE REPORTS

### Case 1: Degloved Thumb

A 41-year-old man, amputated his left nondominant thumb in a conveyor belt machine during a farming accident. Amputation occurred at the level of the interphalangeal joint. The thumb's skin was avulsed up to the dorsum of the hand. Replantation was attempted in another clinic

and resulted in complete soft tissue necrosis. The patient was admitted to our clinic 4 days after injury (Fig. 3A).

The patient refused any surgery to the foot, i.e. harvesting the wrap-around flap, but was receptive to a microsurgical transfer of DLAF. After surgical debridement and distal phalanx resection, a 9 × 14 cm DLAF was tailored in a heart-shaped fashion, with its tip extending proximal to the lateral epicondyle, to include the most distal cutaneous perforator of the PRCA and the PCNF (Fig. 3 B). Anastomoses were performed end-to-side to the radial artery at the distal forearm and end-to-end to the 2 venae comitantes of the radial artery. The PCNF was connected to DSB-RN.

The flap healed uneventfully (Fig. 3C), the donor site was closed primarily and no complications occurred (Fig. 3D). The flap showed some bulkiness in its proximal part, which reduced spontaneously during the first 6 months postoperatively. At 51 months follow-up, thumb opposition scored 5 according to Kapandji scale. Pinch strength was 19 kg, equal to 69% of the contralateral side. Sensibility recovered to protective sensation with some discrimination. The patient returned to his previous job; satisfaction scored 10 for the donor site and 8 for

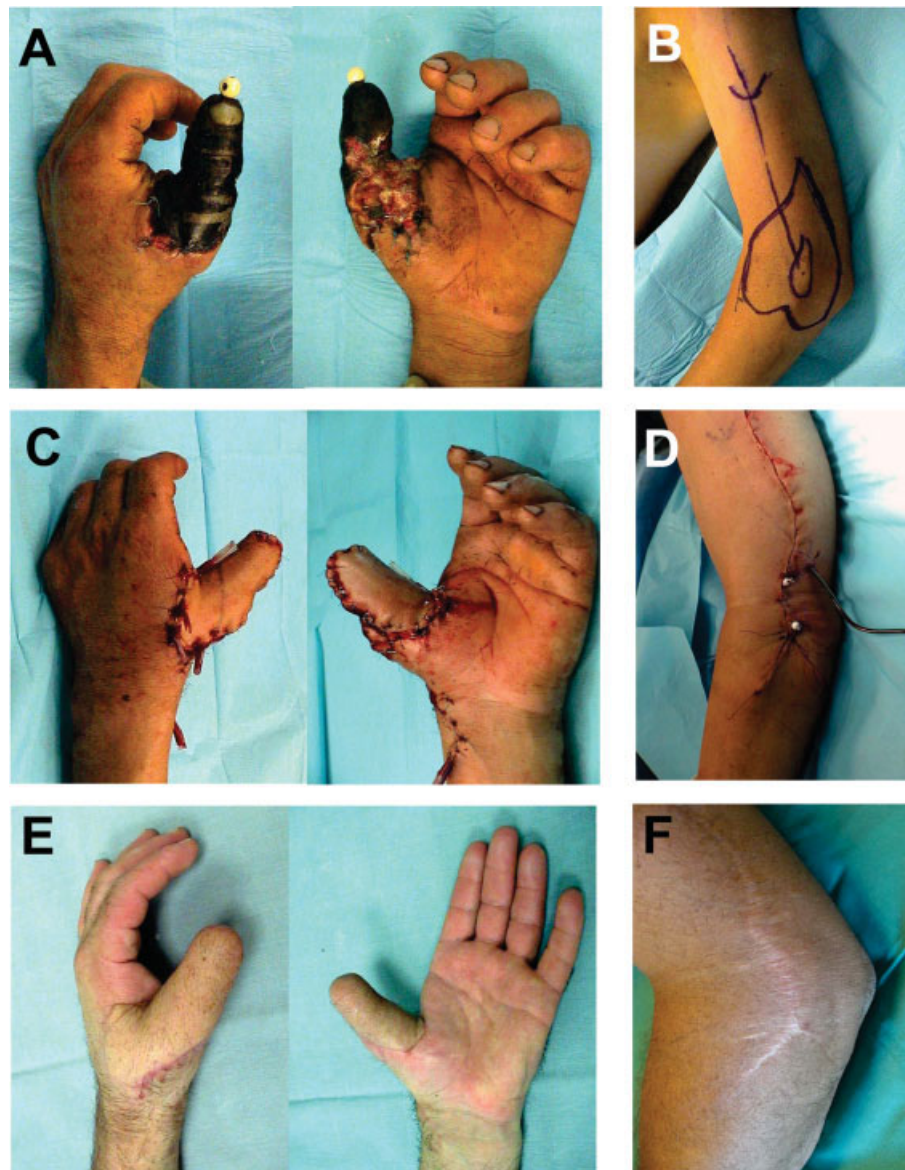


Figure 3. Preoperative view of complete skin necrosis of the degloved left thumb (A). The DLAF is outlined over the lateral epicondyle (B). Intraoperative view of the resurfaced thumb (C) and the primarily closed donor site (D). Appearance of the thumb (E) and donor site (F) after 4 years follow-up. [Color figure can be viewed in the online issue, which is available at [www.interscience.wiley.com](http://www.interscience.wiley.com).]

the resurfaced thumb (Fig. 3E). The donor site showed a complete ROM, in presence of a painless, slightly widened scar (3 mm), no paresthesias or residual pain were experienced over the lateral epicondyle or proximal forearm (Fig. 3F).

### Case 3: Involvement of a Single Finger

A 44-year-old man injured the index finger of his left hand with a rotating machine. The resulting defect was located on finger's radial side, and extended from slightly proximal to the metacarpo-phalangeal joint up to the distal interphalangeal joint, going deep to the shaft of the proximal phalanx. The lateral band of the extensor tendon was cut away, but the radial neurovascular pedicle was preserved (Fig. 4A).

After debridement, the wound showed a  $13 \times 4$  cm residual area of soft tissue loss. A DLAF of proper dimension (Fig. 4B) was transferred and revascularized end-to-side to the radial artery at the anatomical snuff-box, and end-to-end to its venae comitantes. The PCNF was not included in the flap and therefore no nerve suture was performed at the recipient site. The donor site was closed primarily. No complications occurred. At the level of the metacarpo-phalangeal joint, the proximal part of the flap looked rather bulky, but the patient did not require any further operations. This bulkiness reduced spontaneously and was acceptable at 1-year follow-up.

At final follow-up, 68 months postoperatively, the finger recovered full ROM and the pinch test demonstrated 90% of the contralateral side's strength (23 kg). The flap

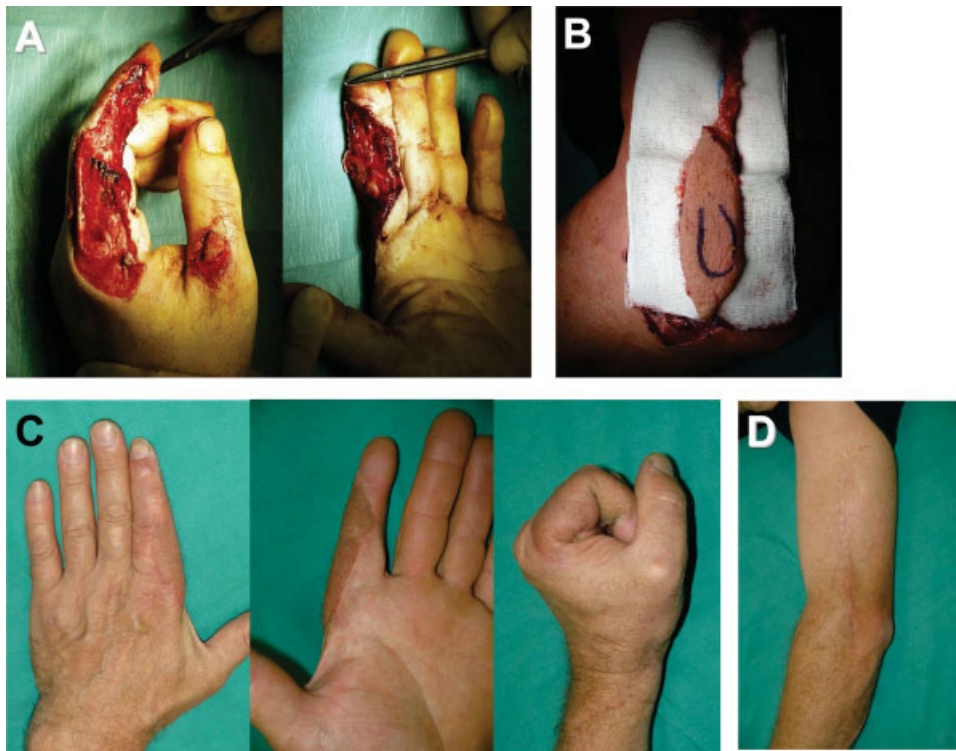


Figure 4. Preoperative view of extensive soft tissue defect of the left index (A). A 13 × 4 cm DLAFLAP was required to cover the defect (B). At 5.5-year follow-up, the finger recovered good appearance and full function (C) and the donor site showed a fairly linear painless scar (D). [Color figure can be viewed in the online issue, which is available at [www.interscience.wiley.com](http://www.interscience.wiley.com).]

regained a partial sensate innervation, but the patient still complained for cold intolerance. This patient returned full-time to his previous job and leisure activities, and was very satisfied with the result (donor site: 10; recipient site: 9-Fig. 4C). The donor site showed a fairly linear painless scar (Fig. 4D). The elbow preserved normal ROM in absence of any tenderness or paresthesia over the donor site and proximal forearm.

#### Case 5: Involvement of Two Adjacent Fingers

A 55-year-old man had the long and ring fingers of his right, nondominant hand caught in a rotating machine. Both fingers showed extensive skin loss of the palmar surface, measuring 5 × 3 cm and 7 × 2.5 cm for middle and ring finger respectively (Fig. 5A). The injury caused complete resection of the profundus flexor tendons, abrasion of the sublimis flexor tendons, and erosion of the distal interphalangeal joints (DIPJ), which were consequently fused. Radial collateral digital nerves were spared in both fingers.

Reconstruction was planned using a single DLAFLAP, measuring 6 × 7 cm (Fig. 5B), to resurface both fingers in temporary syndactyly (Fig. 5C). While the distal part of the flap, containing the thinner skin from the forearm, was used to resurface the defect, the thicker proximal part was placed slightly redundant to protect the anastomosis site at the distal palm. End-to-end arterial anastomosis was performed to the ulnar collateral digital artery of the long fin-

ger and venous anastomosis was to a dorsal vein from the third web space. The PCNF was connected to the ulnar collateral nerve of the long finger in the palm.

At 3 days postoperatively, the flap developed mild venous congestion, due to kinking of the flap, which was treated by splinting of the fingers in full extension for 10 days. The flap survived completely and 1 month after surgery the fingers were released from syndactyly. The proximal part of the flap was resected, taking care to preserve the neurovascular bundle in continuity with the long finger's portion of the flap. Postoperative healing was uneventful. No further flap debulking was necessary and the patient refused any other treatment, such as flexor tendon tenolysis or reconstruction.

As could be expected from the severity of the initial injury, at 41 months follow-up, the fingers recovered 30% ROM and 68 and 63% pinch strength compared with the nonoperated long and ring finger, respectively. Flaps reinnervated partially and no difference was detected between the flap to the ring finger and the one to the long finger, the latter being reinnervated via the PCNF. Despite the limited functional recovery, the patient resumed full use of his nondominant hand and returned to his previous job. The flaps developed some hyperpigmentation and, following resumption of heavy tasks, transient hyperkeratosis was noted (Fig. 5D). The patient's satisfaction scored 10 for the donor site and recipient fingers. The donor site, which was closed primarily,

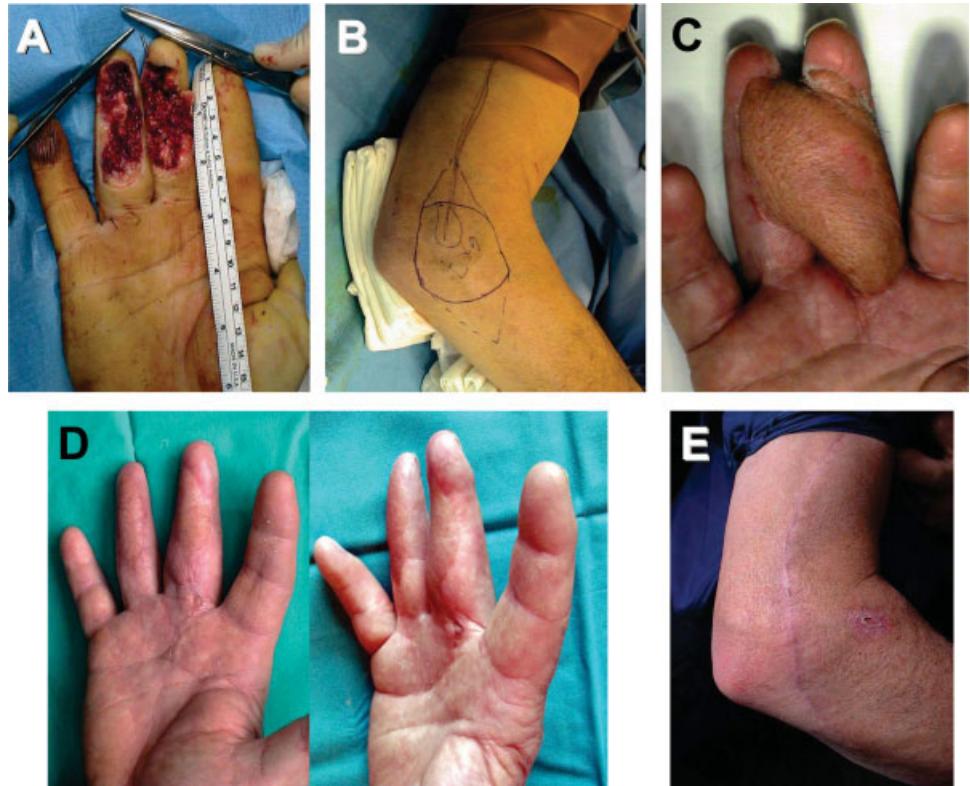

Figure 5. Soft tissue defect of the long and ring fingers (A). A single 6 × 7 cm DLAF (B), was used to cover both finger defects in temporary syndactyly. The thicker proximal part of the flap part extended to the palm to protect the anastomosis site (C). At 3.5-year final follow-up, the patient was completely satisfied with recipient fingers (D) and donor site (E) appearance. [Color figure can be viewed in the online issue, which is available at [www.interscience.wiley.com](http://www.interscience.wiley.com).]

showed a rather enlarged (3 mm) painless scar (Fig. 5E). Neither restriction of ROM nor any tenderness or paresthesia was detectable at the elbow and proximal forearm.

## RESULTS

Results are summarized in Table 2.

All the DLAF survived completely. In 1 case mild venous congestion developed due to flap kinking and resolved after kink removal. One case was reoperated due to osteomyelitis of the distal phalanx and treated by debridement and bone shortening. The successive postoperative course was uneventful, adequate skin coverage was achieved in all cases, no defatting procedures were required. All donor sites were closed primarily and no surgical revision was needed.

Patients were assessed at 53.4 months average follow-up (range 41–68). As compared with the nonoperated limb, elbow ROM averaged 98%, as it was slightly reduced (90%) in 1 patient only. Scar was painless, but enlargement was present in all but 1 patient, averaging 4 mm (range 1–6). Epicondylar pain was absent in all patients. Neither paresthesia nor painful areas were detected over the proximal forearm.

Functional recovery of the recipient thumbs scored five according to Kapandji opposition scale. Recovery of finger ROM averaged 50.75% (range 30–100%) according to TAM criteria. Pinch strength was 72.5% of contralateral side on average (range 65–90%). Sensibility recovery was rather poor. At best, protective sensation with some touch localization was achieved, no difference was detectable between reinnervated and nonreinnervated flaps.

While 4 patients returned to their previous work, 1 patient retired for reasons unrelated to hand injury. All patients were quite satisfied with the donor site appearance and function. Patients satisfaction for the resurfaced fingers and thumbs averaged 8.9 (range 8–10). Dissatisfaction was due to some hair persistence and hyperpigmentation (4 cases) and cold intolerance (2 cases). Hyperkeratosis developed in 3 patients, in which the DLAF was transferred to cover the grasping surface of the digits (Table 2).

## DISCUSSION

The LAF<sup>34</sup> is a versatile transfer for resurfacing small to middle-sized defects mainly in the hand and upper limb. The LAF can also be used as a sensate flap when the posterior cutaneous nerve of the upper arm

Table 2. Results of Digit Resurfacing with DLAF

Case	Injured digit/side	Flap dimension (cm × cm)	Flap survival	Complications/reoperation	Follow-up (months)	Donor site morbidity				Digital recovery				Return to previous work	Patient satisfaction (donor/recipient site)
						Elbow ROM	Scar widening/pain	Forearm paressthesia/pain	ROM	Pinch strength	Static/Dynamic 2-PD test	S - W Test			
1	Thumb/L	9 × 14	Complete	None	51	100%	4/0	0/0	K = 5	69%	15/12	3.61	Yes	10/8	
2	Thumb/L	8 × 13	Complete	None	49	100%	6/0	0/0	K = 5	73%	15/10	3.61	Yes	10/8	
3	Index/L	4 × 13	Complete	None	68	100%	1/0	0/0	S = 100%	90%	20/15	4.31	Yes	10/9	
4	Middle/L	4 × 13	Complete	Osteomyelitis of distal phalanx + marginal necrosis/debridement	58	90%	6/0	0/0	S = 43%	65%	> 20/15	6.65	Retired	10/8	
5*	Middle/R Ring/R	6 × 7	Complete	Mild venous congestion/autonomisation	41	100%	3/0	0/0	S = 30 % S = 30 %	73% 65%	20/15 20/15	4.31 4.31	Yes	10/10 10/10	
Mean					53.4	98%	4/0	0/0	K = 5 S = 50.75%	72.5%				10/8.9 Good: 100%/100%	

\*Skin defect involved two adjacent fingers and was treated by a single flap in temporary syndactyly. Elbow ROM and Pinch Strength evaluation are expressed as percentage of the contralateral side. Scar widening was measured in millimetres.

Pain, paresthesia, and patient's satisfaction are measured according to 10-points Visual Analogic Scale (VAS).

K: Evaluation of thumb opposition by Kapandji scale (0–10).

S: Evaluation of finger's ROM by Strickland's TAM method (0–100%).

S-W: Semmes-Weinstein monofilament sensory threshold test.

(PCNUA) is included into the flap.<sup>35</sup> However, the bulkiness of the flap and the shortness of its vascular pedicle have restricted its use.<sup>25,36,37</sup> The extended lateral arm flap (ELAF) was introduced in the clinical use by Katsaros et al.<sup>23</sup> and Kuek and Chuan<sup>24</sup> as an evolution of the LAF and is characterized by an extension of the LAF skin paddle over and beyond the lateral epicondyle towards the proximal forearm. This modification overcame the main drawbacks of the typical LAF, allowing for inclusion of thinner and more pliable skin from the proximal forearm and a longer pedicle length. Though there are some small differences in drawing and planning, over the years the ELAF has been also called as lateral arm/proximal forearm flap,<sup>37</sup> lateral forearm flap,<sup>38</sup> distally planned LAF,<sup>25</sup> “extreme” LAF,<sup>39</sup> or “true” DLAF.<sup>26</sup> As pointed out by Hage et al.,<sup>26</sup> the “true” DLAF includes only the extended part of the ELAF, consisting of forearm skin only, except for the 4–5 cm skin directly overlying the lateral epicondyle, where the most distal cutaneous perforator of the PRCA is found consistently.<sup>35</sup> The vascular supply of the DLAF relies exclusively on this most distal cutaneous perforator of the PRCA, which continues into the lateral epicondylar anastomotic network, vascularizing the lateral skin of the proximal forearm up to 15 cm beyond the epicondyle.<sup>25,27,37,40</sup>

The DLAF is harvested from the cutaneous area innervated by the PCNF. Therefore, unlike the LAF harvesting technique, only the latter nerve should be included into the DLAF, while the PCNUA, which innervates the LAF, should be left in situ. This surgical detail explains why paresthesia or forearm numbness, present in about 59% of cases after LAF,<sup>36</sup> were negligible in our and other DLAF series.<sup>41</sup>

Other conditions associated to patient dissatisfaction after LAF are lateral epicondylar pain and hypersensitive scar, which are present in 19.4 and 17% of Graham et al.'s series.<sup>36</sup> These conditions may be related to tight wound closure or to the inclusion of the epicondylar periosteum into the flap. In our experience, the latter represents the major reason for this complaint. Such inclusion was avoided routinely in our series and, even though primary closure required significant tensioning of the suture line, our patients did not experience this complication, confirming other investigators' findings.<sup>40</sup> Lastly, satisfactory donor site appearance was reported in only 73% of cases after LAF<sup>36</sup> and in 84% of cases after DLAF.<sup>41</sup> Our series compares favorably with these results, as donor site appearance was considered good in all cases, despite the common finding of scar widening. Furthermore, impairment of elbow function was hardly noticeable. Recovery of ROM and pinch strength of the resurfaced digits were quite satisfactory, if they are considered in correlation with the severity of the initial injury.

Objective measurement of sensibility recovery was poor. Results from reinnervation by collateral sprouting of small nonreinnervated flaps were similar to those of larger flaps who underwent direct reinnervation. In our opinion, these results should not be considered so disappointing, as they correlate strictly to the characteristics of the lateral forearm skin paddle, which has a baseline static or moving 2-point discrimination greater than 15 mm and a pressure threshold evaluated in a range between 2.83 and 3.61 Semmes–Weinstein filaments. When DLAF is used for resurfacing of nongrasping surfaces of the digits, limited recovery of sensibility might not interfere with restoration of manual ability. In our series, all patients returned to previous manual work and showed good satisfaction, even in the cases of the degloved thumb, when a second-staged neurovascular island flap was refused. In addition, even if the DLAF provides a thin and pliable skin paddle, its adherence and shear resistance is inferior to that from a toe transfer. However, patients in our series showed limited functional complaint related to this issue, even in cases of thumb reconstruction. Patients' satisfaction with the appearance of the recipient site was less than optimal due to the presence of hair and the absence of the nail complex in the thumb. These limitations were always accepted by the patients well before the operation, as an exchange for preserving foot integrity.

Since reconstruction of soft tissue defects of the digits require painless skin coverage, having at least protective sensation and being durable enough for normal use, the DLAF proved to be effective in providing adequate coverage to middle- to large-sized skin losses of the finger and thumb, with very low donor site morbidity. In conclusion, the DLAF can be considered as an alternative to foot- or toe-to-hand transfers, when this latter option is not available, due to previous trauma or patient refusal.

## REFERENCES

- Allen MJ. Conservative treatment of finger tip injuries in adults. *Hand* 1980;12:257–265.
- Beasley RW. Principles of soft tissue replacement for the hand. *J Hand Surg* 1983;8:781–784.
- Martin C, Gonzales del Pino J. Controversies in the treatment of fingertip amputations. *Clin Orthop* 1998;63–73.
- Foucher G, Koury RK. Digital reconstruction with hand flaps. *Clin Plast Surg* 1997;24:1–32.
- Bertelli JA, Pagliei A. Direct and reversed flow proximal phalangeal island flaps. *J Hand Surg A* 1994;19:671–680.
- Tremolada C, Ponzilli P, Candiani P, Donati L. The subcutaneous laterodigital reverse flap. *Plast Reconstr Surg* 1998;101:1070–1074.
- Adani R, Marcoccio I, Tarallo L, Fregni U. The reverse heterodigital neurovascular island flap for digital pulp reconstruction. *Tech Hand Up Extrem Surg* 2005;9:91–95.
- Vuppalapati G, Oberlin C, Balakrishnan G. Distally based dorsal hand flaps: Clinical experience, cadaveric studies and an update. *BJPS* 2004;57:653–667.
- Masquelet AC. The posterior interosseous flap in surgery of the hand. *Atlas Hand Clin* 1998;3:109–118.
- Cavadas PC. Posterior interosseous free flap with extended pedicle for hand reconstruction. *Plast Reconstr Surg* 2001;108:897–901.
- Chuang DCC, Colony LH, Chen HC, Wei FC. Groin flap design and versatility. *Plast Reconstr Surg* 1989;84:100–107.
- Yamada N, Ui K, Uchinuma E. The use of a thin abdominal flap in degloving finger injuries. *Br J Plast Surg* 2001;54:434–438.
- Lee WPA, Salyapongse AN. Thumb reconstruction. In: Green DP, Hotchkiss RN, Pederson WC, Wolfe SW, editors. *Green's Operative Hand Surgery*, 5th ed. New York: Churchill Livingstone; 2005. pp 1865–1912.
- Chia J, Lim A, Peng YP. Use of an arterialized venous flap for resurfacing a circumferential soft tissue defect of a digit. *Microsurgery* 2001;21:374–378.
- Turner A, Ragowansi R, Hanna J, Teo TC, Blair JW, Pickford MA. Microvascular soft tissue reconstruction of the digits. *J Plast Reconstr Aesthet Surg* 2006;59:441–450.
- Seradge H, Adham MN, Seradge E, Hunter D. Free vascularized temporal parietal flap in hand surgery. *Orthopedics* 1995;18:1083–1085.
- Morrison WA, O'Brien B McC, MacLeod AM. The foot as a donor site in reconstructive microsurgery. *World J Surg* 1979;3:43–52.
- Rose EH, Buncke HJ. Free transfer of a large sensory flap from the first web space and dorsum of the foot including the second toe for reconstruction of a mutilated hand. *J Hand Surg* 1981;6:196–199.
- Koshima I, Urushibara K, Inagawa K, Hamasaki T, Moriguchi T. Free medial plantar perforator flaps for the resurfacing of finger and foot defects. *Plast Reconstr Surg* 2001;107:1753–1758.
- Ishikura N, Heshiki T, Tsukada S. The use of a free medial pedis flap for resurfacing skin defects of the hand and digits. *Plast Reconstr Surg* 1995;95:100–107.
- Pinal F. The indications for toe transfer after “minor” finger injuries. *J Hand Surg B* 2004;29:120–129.
- Kitidumrongsook P, Patradul A, Pataradool K. Resurfacing the degloved thumb up to the interphalangeal joint level with twin extended neurovascular island flaps. *J Hand Surg B* 2006;31:562–565.
- Katsaros J, Schusterman M, Beppu M, Banis JC, Acland RD. The lateral upper arm flap: Anatomy and clinical applications. *Ann Plast Surg* 1984;12:489–500.
- Kuek LB, Chuan TL. The extended lateral arm flap: A new modification. *J Reconstr Microsurg* 1991;7:167–173.
- Hamdi M, Coessens BC. Distally planned lateral arm flap. *Microsurgery* 1996;17:375–379.
- Hage JJ, Woederman LAE, Smeulders MJC. The truly distal lateral arm flap. Rationale and risk factors of a microsurgical workhorse in 30 patients. *Ann Plast Surg* 2005;54:153–159.
- Tan BK, Lim BH. The lateral forearm flap as a modification of the lateral arm flap: Vascular anatomy and clinical applications. *Plast Reconstr Surg* 2000;53:2400–2404.
- Foucher G, Merle M, Michon J. Single stage thumb reconstruction by a composite forearm flap. *J Hand Surg* 1984;9:245–248.
- Kapandji IA. Clinical evaluation of the thumb's opposition. *J Hand Ther* 1992;2:102–106.
- Strickland JW, Glogovac SV. Total active motion. *J Hand Surg* 1980;5:537–543.
- Bell-Krotoski J, Fess EE, Figarola JH, Hiltz D. Threshold detection and Semmes–Weinstein monofilaments. *J Hand Ther* 1995;8:155–162.
- Callahan AD. Sensibility assessment: Prerequisites and techniques for nerve lesions in continuity and nerve laceration. In: Hunter JM, Mackin EJ, Callahan AD, editors. *Rehabilitation of the Hand: Surgery and Therapy*. St. Louis: CV Mosby; 1995. pp 129–153.
- Dellon AL. The moving two point discriminator test: Clinical evaluation of the quickly-adapting fiber/receptor system. *J Hand Surg* 1978;3:474.
- Song R, Song Y, Yu Y, Song Y. The upper arm free flap. *Clin Plast Surg* 1982;9:27–35.
- Hennerbichler A, Etzer C, Gruber S, Brenner E, Papp C, Gaber O. Lateral arm flap: Analysis of its anatomy and modification using a



- vascularized fragment of the distal humerus. *Clin Anat* 2003;16:204–214.
36. Graham B, Adkins P, Schecker LR. Complications and morbidity of the donor and recipient sites in 123 lateral arm flaps. *J Hand Surg B* 1992;17:189–192.
  37. Brandt KE, Khouri RK. The lateral arm/proximal forearm flap. *Plast Reconstr Surg* 1993;92:1137–1143.
  38. Lanzetta M, Bernier M, Chollet A, St. Laurent JY. The lateral forearm flap: An anatomic study. *Plast Reconstr Surg* 1997;99:460–464.
  39. Casoli V, Kostopoulos E, Pelissier P, Caix P, Martin D, Baudet J. The middle collateral artery: Anatomic basis for the “extreme” lateral arm flap. *Surg Radiol Anat* 2004;26:172–177.
  40. Ninkovic M, Harpf C, Schwabegger AH, Rumer-Moser A, Ninkovic M. The lateral arm flap. *Clin Plast Surg* 2001;28:367–374.
  41. Hamdi M, Coessens BC. Evaluation of the donor site morbidity after lateral arm flap with skin paddle extending over the elbow joint. *Br J Plast Surg* 2000;53:215–219.